

Data Sheet

8-OHdG (8-Hydroxy-2'-deoxyguanosine)

ANTIBODY, MONOCLONAL

Catalog no.:	AA1005.1 / AA1005.2
Immunogen:	8-OHdG keyhole limpet hemocyanin-conjugated
Host:	Mouse
Clone no.:	N45.1
Isotype:	IgG ₁ (kappa)
Matrix:	Ascites, ammonium sulphate purified, 10 mM Phosphate buffered saline, pH7.4, 1.0% BSA
Specificity:	8-OHdG in human, rabbit, rat and mouse tissue and cells

There was no cross reactivity obtained with 19 analogues of 8-OHdG: guanosine (G), 7-methyl-G, 6-SH-G, 8-bromo-G, dA, dC, dT, dI, dU, dG, O⁶-methyl-dG, 8-OHdA, guanine (Gua), O⁶-methyl-Gua, 8-OHGua, uric acid, urea, creatine, creatinine. Only 8-sulphydryl-G and 8-OHG demonstrate minimal cross-reactivity (less than 1%).

Contents:	20 µg / 100 µg (lyophilized) Resuspend in 200 µl / 1000 µl aqua bidest. for 100 µg/ml
------------------	--

Known applications:	ELISA ³ , immunohistochemistry (paraffin sections, 3-5 µg/ml) ^{1, 2, 3, 4, 5, 6} , immunocytochemistry ⁷
----------------------------	---

This antibody has not been tested for use in all applications. This does not necessarily exclude its use in non-tested procedures. The stated dilutions are recommendations only. End users should determine optimal dilutions in their system using appropriate negative/positive controls.

Store at:	- 20 °C
------------------	---------

Repeated thawing and freezing must be avoided

References:	1. Hattori Y, Nishigori C, Tanaka T, Uchida K, Nikaido O, Osawa T, Hiai H, Imamura S, Toyokuni S (1996). 8-hydroxy-2'-deoxyguanosine is increased in epidermal cells of hairless mice after chronic ultraviolet B exposure. <i>J Invest Dermatol</i> 107 (5): 733-737.
--------------------	---

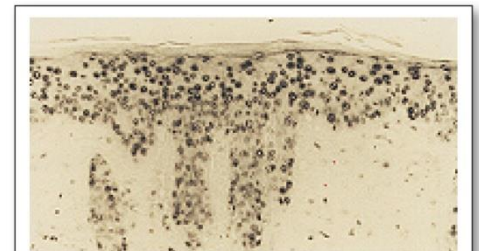
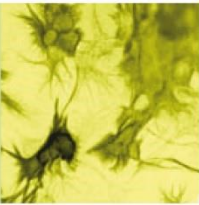
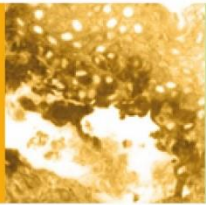


Figure 1: Immunohistochemistry image of 8-OHdG staining in paraffin section of UV-irradiated mouse skin. Antigen retrieval was performed in 0,1% trypsin. The section was incubated with AA1005 (5µg/ml), followed by staining with avidin-biotin-complex method. AA1005 stains epidermal cells and some infiltrating neutrophils and macrophages

Hattori Y et al. (1996) *J Invest Dermatol* 107(5): 733-737





2. Tanaka T, Nishiyama Y, Okada K, Hirota K, Matsui M, Yodoi J, Hiai H, Toyokuni S (1997). Induction and nuclear translocation of thioredoxin by oxidative damage in the mouse kidney: independence of tubular necrosis and sulfhydryl depletion. *Lab Invest* **77**(2): 145-155.
3. Toyokuni S, Tanaka T, Hattori Y, Nishiyama Y, Yoshida A, Uchida K, Hiai H, Ochi H, Osawa T (1997). Quantitative immunohistochemical determination of 8-hydroxy-2'-deoxyguanosine by a monoclonal antibody N45.1: its application to ferric nitrilotriacetate-induced renal carcinogenesis model. *Lab Invest* **76**(3): 365-74.
4. Ihara Y, Toyokuni S, Uchida K, Odaka H, Tanaka T, Ikeda H, Hiai H, Seino Y, Yamada Y (1999). Hyperglycemia causes oxidative stress in pancreatic beta-cells of GK rats, a model of type 2 diabetes. *Diabetes* **48**(4): 927-932.
5. Kondo S, Toyokuni S, Iwasa Y, Tanaka T, Onodera H, Hiai H, Imamura M (1999). Persistent oxidative stress in human colorectal carcinoma, but not in adenoma. *Free Radic Biol Med* **27**(3-4): 401-410.
6. Ichiseki T, Kaneuji A, Katsuda S, Ueda Y, Sugimori T, Matsumoto T (2005). DNA oxidation injury in bone early after steroid administration is involved in the pathogenesis of steroid-induced osteonecrosis. *Rheumatology (Oxford)* **44**(4): 456-460.
7. Lee YA, Cho EJ, Yokozawa T (2008). Protective effect of persimmon (*Diospyros kaki*) peel proanthocyanidin against oxidative damage under H₂O₂-induced cellular senescence. *Biol Pharm Bull* **31**(6): 1265-1269.

Last updated on: 14 April 2022

For research use only

Publishing research using AA1005? Please let us know so that we can cite your publication as a reference.

